



International Journal of Rhinology & Otolaryngology

Case Report

An Unusual Cause of Nasal Mass: Metastatic Papillary Thyroid Carcinoma to Nasal Cavities and Paranasal Cavities -

Omar Iziki*, Kaoutar Chaker, Ahmed B Ahmedou, Sami Rouadi, Redallah Abada, Mohamed Roubal and Mohamed Mahtar

Department of Otorhinolaryngology, Head and Neck Surgery, King Hassan II University & Ibn Rochd Hospital of Casablanca, Morocco

***Address for Correspondence:** Omar Iziki, Department of Otorhinolaryngology, Head and Neck Surgery, King Hassan II University, Ibn Rochd Hospital, Casablanca, Morocco, Tel: +212-061-395-3181; E-mail: omar.iziki@gmail.com

Submitted: 31 May 2019; **Approved:** 04 June 2019; **Published:** 05 June 2019

Cite this article: Iziki O, Chaker K, Ahmedou AB, Rouadi S, Abada R, et al. An Unusual Cause of Nasal Mass: Metastatic Papillary Thyroid Carcinoma to Nasal Cavities and Paranasal Cavities. Int J Rhinol Otolological. 2019;2(1): 005-007.

Copyright: © 2019 Iziki O, et al. This is an open access article distributed under the Creative Commons Attribution License, which permits unrestricted use, distribution, and reproduction in any medium, provided the original work is properly cited.

ABSTRACT

Metastatic papillary thyroid carcinoma typically appears in local lymph nodes, nasal and skull base metastases are rare. The authors describe the third case of Metastatic papillary thyroid carcinoma to nasal cavities and paranasal cavities in the literature. The objective of this study is to describe - from our clinical case and from literature review- the clinical radiological features of this rare entity, and to discuss its therapeutic management. Until now, there is not enough data on postoperative radioactive iodine ablation, external radiation, or chemotherapy, but early diagnosis is essential for an ideal care. It seems that surgical approach is one of the best methods to manage and eradicate this type of tumor.

Keywords: Papillary thyroid carcinoma; Nasal cavities; Paranasal cavities; Metastase

INTRODUCTION

Papillary Thyroid Cancer (PTC), the most common thyroid malignancy, is associated with an excellent prognosis. It is a well-differentiated malignant tumor, which accounts for 1% of all malignant tumors. Metastatic thyroid carcinoma usually appears in the local lymph nodes. Indeed, distant metastases of papillary thyroid carcinoma are uncommon and the most common site of metastasis is lung followed by bone. PTC metastatic to nasal and paranasal region is extremely rare and only 2 cases have been reported in the English scientific literature until April 2019 [1,2]. In this article authors describe the third case of distant metastasis of a PTC to nasal cavities and paranasal sinuses.

CASE REPORT

A 69-year-old female, without important pathological antecedents, referred to our center in the ENT department of Head and Neck Surgery at the King Hassan II University of Casablanca by an ophthalmologist with one-sided progressive exophthalmos, nasal obstruction and epistaxis, for more than seven months.

Physical examination, revealed a large goiter, neglected over than 14 years according to the patient, with a discrete left exophthalmos, and reduction of visual acuity in the same side (Figure 1).

Nasal examination showed a dark pink mass occupying the totality of the left nasal cavity.

Computed Tomography (CT) of the Paranasal Sinuses (PNS) revealed a polypoid soft-tissue mass located in the left nasal cavity, left maxillary and sphenoidal sinuses, with an invasion orbital apex, the optic canal and the skull base (Figure2).

A biopsy of nasal mass was performed under local anesthesia followed by a massive bleeding managed by a nasal packs.

Histopathological examination revealed papillary cell carcinoma (Figure 3).

Patient underwent a total thyroidectomy. Followed by scintigraphy, showing fixation on nasal, paranasal cavities and skull base, with no other metastasis. Final decision was to perform a palliative radiation therapy.

DISCUSSION

Papillary Thyroid Carcinoma (PTC) derives from the thyroid follicular epithelial cells. It's the most common malignant thyroid neoplasm in countries with sufficient iodine diets and comprises up to 80% of all thyroid malignancies [3]. This malignant tumor remains latent and does not or very slowly grow and associated with a low mortality rate. While lymph node metastases are often present at diagnosis (average about 50%, can be as high as 85-90% in some

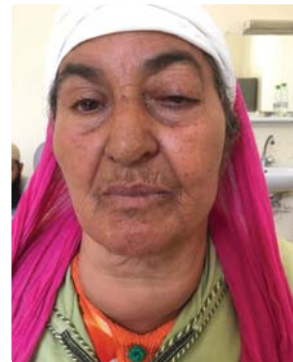

Figure 1: Photograph shows a large goiter, with a left exophthalmos.

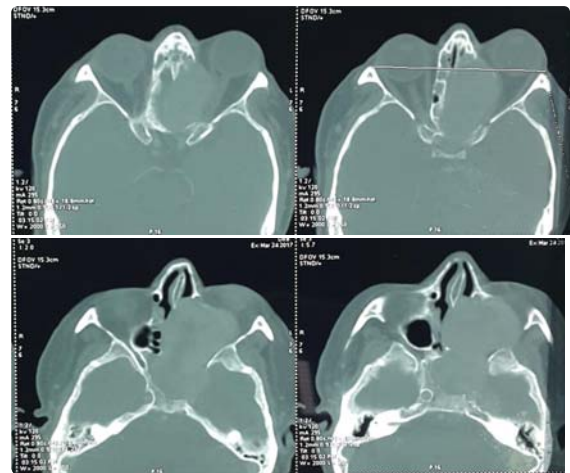


Figure 2: CT scan show the PTC of the nasal and paranasal cavities with invasion of orbit optic canal and skull base.

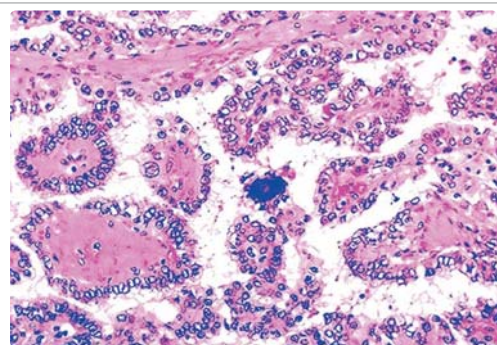


Figure 3: Papillary thyroid carcinoma configuration on histologic examination.



series), haematogenous spread is rather a rare and late event [4]. In contrast, distant metastases are very frequently found in children and adolescents [5]. The most common sites of distant metastases reported in literature are bone and lungs and less commonly brain, liver, bladder, and skin. Bone metastases can occur in the vertebral bodies followed by the pelvis, femur and skull. They are the principal cause of death in well-differentiated thyroid carcinoma cases is distant metastasis [6].

Metastases of thyroid carcinoma to PNS are fairly uncommon, few cases have been reported, dominated by undifferentiated or follicular thyroid carcinoma [7]. To our best knowledge, only 2 cases of PTC metastatic to nasal and paranasal cavities have been documented in the literature until 2018 [1,2].

Madan et al. in 2013 presented the first case, a 45-year-old male with a large mass in the left side of nasal cavity that caused the destruction of the nasal septum and sphenoid wing, erosion of sphenoid and ethmoid sinus, involvement of cavernous sinus and expansion of medial wall of both orbits. The patient underwent radiation therapy. According to their reports, no significant changes were demonstrated in comparison to baseline imaging and patients had stable disease [2].

The second case of PTC metastatic to nasal and paranasal cavities has been published in 2018 by Pourseirafi et al. [1]. They reported a 55-year-old female with one-sided nasal obstruction and rhinorrhea in her nose. She was a known case of papillary thyroid carcinoma with metastases to the pelvic and lung. Patient's PNS CT with contrast revealed an irregular border mild enhancing tumoral solid mass measuring 30×30 mm at the anterior inferior of the right nasal cavity without calcification or lytic osseous lesion at adjacent bone and PNS were clear [1]. The mass was removed by Functional endoscopic sinus surgery.

There's no treatment algorithm or clear consensus for management of PTC in the skull base and paranasal cavities. Based on a case series of five solitary follicular thyroid carcinomas of the skull base, Rosahl et al. [4] proposed a simple treatment algorithm. The authors suggested that 131-I whole body scan and thyroidectomy are indicated if a diagnosis of skull base metastasis of differentiated thyroid cancer is made [5]. If 131-I uptake is detected, postoperative radioiodine ablation therapy should be freely implemented.

Conversely, in the absence of 131-I uptake, external beam radiation therapy was stressed [3].

In our case, we performed a total thyroidectomy given the volume of goiter. Surgery was not possible; tumor was large and had a massive invasion of the skull base. Our patient underwent a palliative radiation therapy.

CONCLUSION

To the best of our knowledge, we have presented the third report of PTC in the nasal cavity. There is not enough data on postoperative radioactive iodine ablation, external radiation, or chemotherapy, but early diagnosis is essential for an ideal care. It seems that surgical approach is one of the best methods to manage and eradicate this type of tumor.

REFERENCES

1. Pourseirafi S, Shisheghar M, Ashraf MJ, Faramarzi M. Papillary carcinoma of thyroid with nasal cavity metastases: A case report. *Iran J Med Sci.* 2018; 43: 90-93. <https://bit.ly/2K3TqZ1>
2. Madan R, Goyal S, Dinda AK, Maohanti BK. Papillary carcinoma of thyroid with paranasal sinus metastases. *Clin Cancer Investig J.* 2013; 2: 90-92. <https://bit.ly/2lpHeHE>
3. Kum RO, Aygenç E, Somuk BT, Borcek P, Ozdem C. A unique case of intranasal metastasis from occult poorly differentiated thyroid carcinoma. *Balkan Med J.* 2015; 32: 316-319. <https://bit.ly/2QITowe>
4. Rosahl SK, Erpenbeck V, Vorkapic P, Samii M. Solitary follicular thyroid carcinoma of the skull base and its differentiation from ectopic adenoma-review, use of galectin-3 and report of a new case. *Clin Neurol Neurosurg.* 2000; 102: 149-155. <https://bit.ly/2wArYZX>
5. Mydlarz WK, Wu J, Aygun N, Olivi A, Carey JP, Westra WH, et al. Management considerations for differentiated thyroid carcinoma presenting as a metastasis to the skull base. *Laryngoscope.* 2007; 117: 1146-1152. <https://bit.ly/2WKfjSW>
6. Krishnamurthy A, Ramshankar V. Multiple paranasal sinus involvement from a metastatic follicular carcinoma thyroid. *Natl J Maxillofac Surg.* 2013; 4: 121-122. <https://bit.ly/2QOnAzD>
7. Varadarajan VV, Pace EK, Patel V, Sawhney R, Amdur RJ, Dziegielewski PT. Follicular thyroid carcinoma metastasis to the facial skeleton: a systematic review. *BMC Cancer.* 2017; 17: 225. <https://bit.ly/2wyQJ8Q>