



International Journal of Ophthalmology & Vision Research

Case Series

Inferior Oblique Z-Myotomy for Hypertropia Correction in Children - ②

Sohraab Yadav*, Areti Bourtoulamaïou, Arvind Chandna and Harish
Nayak

Alder Hey Children's Hospital

***Address for Correspondence:** Sohraab Yadav, Eye Clinic, Alder Hey Children's Hospital, Eaton Road, Liverpool, Merseyside, UK, Tel: +01-512-525-125; Fax: +01-512-280-328; ORCID: 0000-0002-7753-2553; E-mail: sohraab@doctors.org.uk

Submitted: 10 October 2018; **Approved:** 22 October 2018; **Published:** 23 October 2018

Cite this article: Yadav S, Bourtoulamaïou A, Chandna A, Nayak H. Inferior Oblique Z-Myotomy for Hypertropia Correction in Children. Int J Ophthal Vision Res. 2018;2(1): 014-016.

Copyright: © 2018 Yadav S, et al. This is an open access article distributed under the Creative Commons Attribution License, which permits unrestricted use, distribution, and reproduction in any medium, provided the original work is properly cited.

ABSTRACT

Purpose: To report the efficacy of inferior oblique Z-myotomy for the treatment of hypertropia in children.

Methods: Consecutive prospective analysis of all patients undergoing inferior oblique Z-myotomy for the treatment of hypertropia and inferior oblique overaction between June 2011 and June 2015 at a single tertiary centre. Pre- and post-operative hypertropia measurements were compared and analysed using the Wilcoxon signed ranks test.

Results: A total of 8 patients were included in the study. Average age at time of surgery was 7.6 years. Average hypertropia measurements in primary position improved from 8.4 prism dioptres pre-operatively to 3 prism dioptres post-operatively for distance and from 6.9 prism dioptres pre-operatively to 2 prism dioptres post-operatively for near at final follow-up ($p < 0.05$). Inferior oblique overaction and acquired head posture resolved post-operatively in all cases.

Conclusions: Inferior oblique Z-myectomy is a simple and effective procedure for the management of hypertropia in the paediatric population.

INTRODUCTION

Vertical strabismus typically poses a greater management challenge than horizontal deviations. Small deviations can occasionally be managed with prisms but surgery is preferred for the majority of cases [1]. Hypertropia may be treated using inferior oblique surgery depending on the causes identified during orthoptic assessment. The traditional approaches used for this muscle include myectomy, disinsertion and recession [2]. Here we describe the outcomes of inferior oblique Z-myotomy for the management of hypertropia resulting from inferior oblique overaction, previous surgery or superior oblique palsy.

METHODS

All patients with hypertropia undergoing inferior oblique Z-myotomy during a 4 year period (between June 2011 and June 2015) were included in the study. Stable oculomotor examinations were obtained by orthoptists on at least 2 previous occasions prior to listing for surgery.

Surgery was performed by the 2 senior authors (AC and HN). Patients underwent a conjunctival incision 8mm from the limbus in the infero-temporal quadrant and blunt dissection was performed to identify the inferior oblique muscle. The muscle belly was isolated between two muscle clamps 10mm apart. Approximately 75% of the muscle width was cut and cauterised adjacent to the clamps to leave a longer muscle with a Z pattern once released (Figure 1). The conjunctiva was closed using 8/0 Vicryl sutures. Subtenon chirocaine injection, topical Voltarol and topical chloramphenicol were used at the end of the procedure.

Patients were followed-up at regular intervals in the post-operative, orthoptist and optometrist clinics to obtain measurements. Pre- and post-operative measurements were compared and analysed using the Wilcoxon signed ranks test (IBM SPSS v21). Presence of symptomatic diplopia and acquired head posture were also compared pre- and post-operatively.

RESULTS

A total of 8 patients underwent inferior oblique Z-myotomy for hypertropia during the study period. Patient characteristics and results are summarised in the table 1. The mean age was 7.6 years (range 5 to 11 years). Mean follow-up was 226 days. A statistically significant reduction in hypertropia measurements was observed. Average hypertropia measurements in primary position improved from 8.4 prism dioptres pre-operatively to 3 prism dioptres post-operatively for distance and from 6.9 prism dioptres pre-operatively

to 2 prism dioptres post-operatively for near at final follow-up ($p < 0.05$). Average maximum hypertropia (maximum measured in any direction of gaze) was also significantly reduced from 14.3 prism dioptres pre-operatively to 3.8 prism dioptres post-operatively at final follow-up ($p < 0.05$). Inferior oblique overaction when present resolved post-operatively. Symptomatic diplopia and acquired head posture resolved in all cases.

DISCUSSION

Here we have demonstrated good outcomes using inferior oblique Z-myotomy in patients with symptomatic hypertropia. In contrast to previous studies which have mainly used this technique for small hypertropias [3], we have shown that it is applicable to hypertropias as large as 18 prism dioptres. Furthermore, this technique should be considered not just for inferior oblique overaction, but also for other causes of hypertropia such as superior oblique palsy and consecutive hypertropia.

As well as the favourable surgical outcomes, the technique also has practical advantages over the traditional approaches. Access to the inferior oblique muscle may be difficult due to its proximity to the inferior and lateral rectus [4]. Therefore recession of the muscle is more time consuming leading to higher theatre costs and anaesthetic risk for the patient. The risk inherent to traditional muscle detachment and reattachment techniques such as scleral perforation and macular damage [5] are also avoided with the Z-myotomy technique. Inferior oblique myectomy is a quick procedure but can leave patients with a significant overcorrection [4]. The risks with Z-myotomy may be lower as there is a degree of treatment titration.

The main limitation of our study is the relatively small sample size. However, our encouraging results indicate that inferior oblique Z-myotomy should be considered as a useful alternative technique for the management of patients with symptomatic hypertropia.

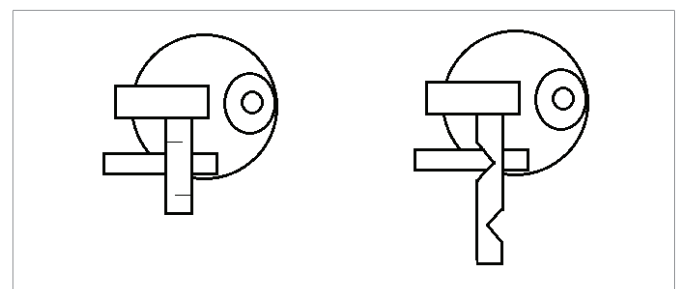


Figure 1: Inferior oblique z-myotomy schematic diagram. The inferior oblique is lengthened using 2 partial thickness incisions.

Table 1:

Patient ID	Age (years)	Sex	Diagnosis	Distance hypertropia Pre-Operative (PD)	Distance hypertropia Post-Operative (PD)	Near hypertropia Pre-Operative (PD)	Near hypertropia Post-Operative (PD)
1	11	Male	Superior oblique palsy	2	2	1	2
2	5	Male	Consecutive hypertropia	6	4	6	0
3	5	Male	Consecutive hypertropia	6	4	6	0
4	10	Male	Inferior oblique overaction	12	4	10	6
5	7	Female	Inferior oblique overaction	18	8	18	6
6	8	Female	Superior oblique palsy	3	0	4	0
7	7	Female	Inferior oblique overaction	2	2	2	2
8	8	Male	Consecutive hypertropia	18	8	18	4

REFERENCES

1. Archer SM. Management of paretic vertical deviations. *Am Orthopt J.* 2011; 61: 6-12. <https://goo.gl/qP3s6Z>
2. Sanjari MS, Shahraki K, Nekoozadeh S, Tabatabaee SM, Shahraki K, Aghdam KA. Surgical treatments in inferior oblique muscle overaction. *J Ophthalmic Vis Res.* 2014; 9: 291-295. <https://goo.gl/VQcwKa>
3. Cruz FC, Robbins SL, Kinori M, Acera EC, Granet DB. Z-myotomy of the inferior oblique for small incomitant hypertropias. *J AAPOS.* 2015; 19: 130-134. <https://goo.gl/znk8y2>
4. Gillies WE. Simple technique for recession of the inferior oblique muscle. *Br J Ophthalmol.* 1970; 54: 736-739. <https://goo.gl/XaNhh2>
5. Inferior oblique muscle weakening procedures. In: Farzavandi S, ed. *Color Atlas of Strabismus Surgery*: Springer New York; 2007. p.166-179. <https://goo.gl/omURWD>