



American Journal of Clinical & Medical Images

Clinical Image

Triple Fistula Complicating a Case of Chronic Calculous Cholecystitis - @

Serban Puia Negulescu*, Alexandra Dili and Claude Bertrand

Department of General and Digestive Surgery, University catholique de Louvain, CHU UCL Namur, Av. Docteur G. Thérassé 1, 5530 Yvoir, Belgium

***Address for Correspondence:** Serban Puia Negulescu, Department of General and Digestive Surgery, University catholique de Louvain, CHU UCL Namur, Av. Docteur G. Thérassé 1, 5530 Yvoir, Belgium, E-mail: puiaserban@gmail.com

Submitted: 10 May 2018; Approved: 28 May 2018; Published: 30 May 2018

Cite this article: Negulescu SP, Dili A, Bertrand C. Triple Fistula Complicating a Case of Chronic Calculous Cholecystitis. American J Clin Medical Imag. 2018;1(1): 005-006.

Copyright: © 2018 Negulescu SP, et al. This is an open access article distributed under the Creative Commons Attribution License, which permits unrestricted use, distribution, and reproduction in any medium, provided the original work is properly cited.

ABSTRACT

Upper GI series in a patient with chronic calculous cholecystitis presenting for diarrhea. The images show a large fistula between the gallbladder and the genu superius of the duodenum, a second communication between the gallbladder and the common biliary duct and a third communication between the fundus of the gallbladder and the transverse colon.

MANUSCRIPT

Upper GI series in a patient with chronic calculous cholecystitis presenting for diarrhea: Figure 1: Native image showing a porcelain gallbladder and aerobilia; Figure 2: Early image after barium swallow showing a large fistula between the gallbladder and the genu superius of the duodenum; normal opacification of the duodenum distal to the fistula; Figure 3: Later image confirming the cholecystoduodenal fistula and showing another fistula between the gallbladder and the common biliary duct (trajectory superior to the trajectory of the cholecystoduodenal fistula with the anterograde et retrograde opacification of the common biliary duct); note the irregularity of the lower common biliary duct; fistula between the fundus of the gallbladder and the transverse colon (opacification of numerous colonic diverticula).

These findings were confirmed at surgery.

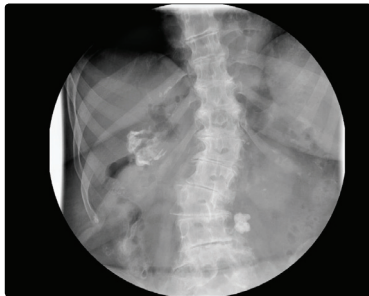

Figure 1:

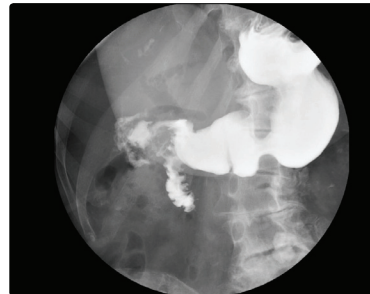


Figure 2:

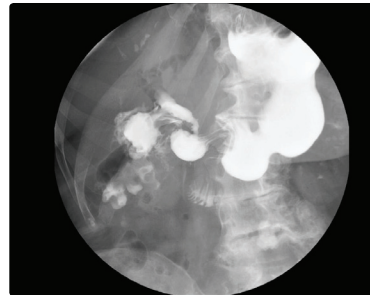


Figure 3: