



# International Journal of Cardiovascular Diseases & Diagnosis

## Case Report

# A Novel Treatment Strategy in the Setting of Heart Block or Cardiac Arrest Secondly to Coronary Artery Spasm -

**Jiang Y. Wang<sup>1\*</sup>, Xi Su<sup>2</sup>, Chen W. Liu<sup>3</sup>, Chen YiXu<sup>4</sup>, Zhi P. Zhang<sup>5</sup>, Dan Song<sup>6</sup>, Jian Peng<sup>7</sup>, Hua Yan<sup>8</sup>**

*Department of cardiology, Wuhan Asia heart hospital, Wuhan, China*

**\*Address for Correspondence:** Xi Su, Department of Cardiology, Wuhan Asia heart hospital, Wuhan 430022, China; Tel: +8615172496706; E-mail: yaxin\_suxi@163.com

**Submitted: 05 May 2017; Approved: 12 May 2017; Published: 16 May 2017**

**Citation this article:** Su X, Wang JY, Liu CW, YiXu C, Zhang ZP, et al. A Novel Treatment Strategy in the Setting of Heart Block or Cardiac Arrest Secondly to Coronary Artery Spasm. Int J Cardiovasc Dis Diagn. 2017;2(1): 008-010.

**Copyright:** © 2017 Su X, et al. This is an open access article distributed under the Creative Commons Attribution License, which permits unrestricted use, distribution, and reproduction in any medium, provided the original work is properly cited.

## ABSTRACT

Coronary artery vasospasm is not yet completely clarified. CAS can lead to sudden cardiac death due to ventricular Coronary Artery Spasm (CAS) is not an uncommon event, but its pathophysiologic mechanisms followed by arrhythmias or heart block. Diltiazem is a core of drugs for the treatment of CAS, but in the setting of heart block or cardiac arrest, administration of the diltiazem may be associated with aggravated heart block or cardiogenic shock. We report a 78-year-old man who had a complete atrioventricular block with ST-segment elevation and a witnessed cardiac arrest with ventricular tachycardia / ventricular fibrillation, which could not be controlled effectively by defibrillations and positive inotropic action drugs. Emergency coronary angiography revealed that the right coronary artery systems diffuse spasm. We timely adjusted the treatment strategy, and the ventricular tachycardia was successfully terminated by administration of intravenous diltiazem.

## INTRODUCTION

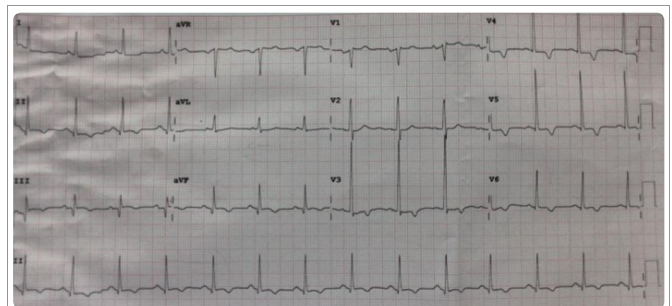
Coronary Artery Spasm (CAS) is not an uncommon event, but its pathophysiologic mechanisms followed by coronary artery vasospasm are not yet completely clarified. Coronary endothelial dysfunction and a variety of nonspecific vasoconstrictive stimuli factors such as  $\alpha$ -adrenergic stimulation,  $\beta$ -adrenergic blockade, and altered sympathovagal balance could be the main causes of coronary artery spasm [1-2]. Patients with coronary artery spasm typically describe chest pain symptoms, usually occurring in the early hours of the morning with ST - segment elevation on Electrocardiogram (ECG). In severe cases, CAS associated arrhythmias may be present ranging from heart block to ventricular tachycardia or cardiac arrest [3]. In the process of cardiopulmonary resuscitation, using large dose of vasoactive drugs might deteriorate CAS. Diltiazem is a core of drugs for the treatment of CAS, but in the setting of heart block or cardiac arrest, administration of the diltiazem may be associated with aggravated heart block or cardiogenic shock [4]. On the surface, in the setting of heart block or cardiac arrest, administration of the diltiazem may be existentially contradictory. But in the setting of heart block or cardiac arrest secondly to CAS, the outcome will be completely different.

## CASE PRESENTATION

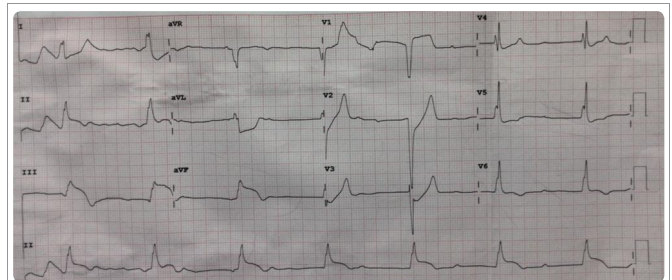
A 78-year-old man with a medical history of hypertension presented to the emergency department of Wuhan Asia heart hospital with a recent onset of intermittent chest pain. Electrocardiography (Figure 1A) and transthoracic immediately, and the ventricular tachycardia was terminated for a while at first, but subsequently, recurrent incessant episodes of ventricular fibrillations were developed, and the patient was required continuous chest compressions, tracheal intubation, and intravenous epinephrine. Because the patient's hemodynamic status continued to worsen, an intra-aortic balloon pump was inserted immediately. Emergency coronary angiography revealed that the entire right coronary artery systems diffuse spasm (Figure 2A). The patient's right coronary artery had a certain improvement by administration of repeatedly intracoronary boluses of nitroglycerin 600ug (Figure 2B). While in the cardiac care unit, a recurrent ventricular tachycardia was terminated by administration of intravenous diltiazem 8 mg (Figure 1D). Since then, no significant ventricular arrhythmias happened anymore with intravenous diltiazem maintenance treatment (Figure 1E). He did not develop heart failure throughout his hospital stay. Seven days later, her follow-up echocardiogram revealed improvement of the ejection fraction to 50%.

## DISCUSSION

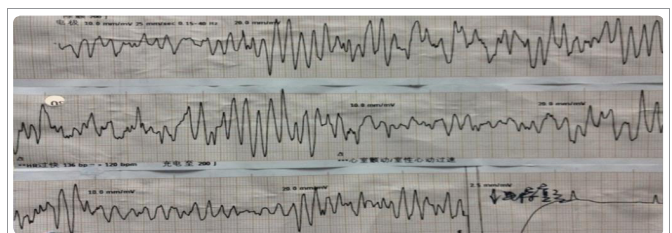
CAS is not an uncommon event, but its pathophysiologic mechanisms followed by coronary artery vasospasm are not yet completely clarified. Coronary endothelial dysfunction and a variety of nonspecific vasoconstrictive stimuli factors such as  $\alpha$ -adrenergic



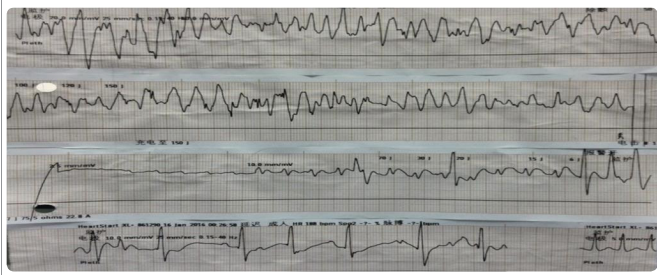**Figure 1A:** The 12-lead ECG results on admission. It demonstrated the changes of ST-T in leads V3 - V6, suggesting ischemia of anterior wall.



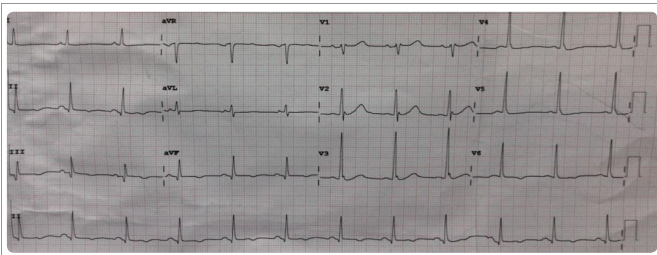
**Figure 1B:** The 12-lead ECG results on hospitalization. It demonstrated third-degree atrioventricular block with ST-segment elevation in leads II, III, and aVF, suggesting ischemia of the right coronary artery. The initial diagnosis was acute inferior wall infarction.



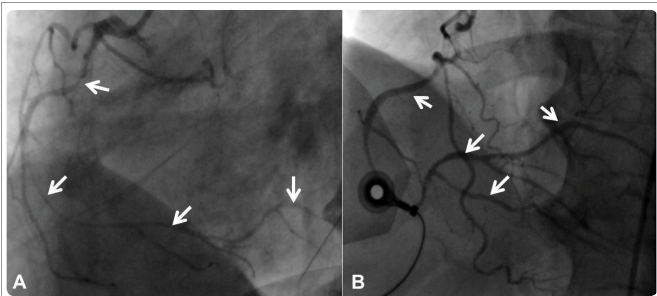
**Figure 1C:** The patient had cardiac arrest with ventricular tachycardia / ventricular fibrillation. Their current incessant ventricular tachycardia / ventricular fibrillation could not be controlled by defibrillations and required continuous chest compressions.



**Figure 1D:** After coronary angiography, recurrence of ventricular tachycardia was successfully converted to accelerated junction rhythm with resolution of the ST-segment elevation by administration of intravenous diltiazem.



**Figure 1E:** The 12-lead ECG results prior to discharge, his ECG showed sinus rhythm with resolution of the ST-segment elevation.



**Figure 2A,B:** A: Emergency Coronary Angiography Revealed That The Entire Right Coronary Artery Systems diffuse spasm (white arrows). B: The patient's right coronary artery had a certain improvement by administration of repeatedly intracoronary boluses of nitroglycerin (white arrows).

stimulation,  $\beta$ -adrenergic blockade, and altered sympathovagal balance could be the main causes of coronary artery spasm [1-2]. Patients with coronary artery spasm typically describe chest pain symptoms, usually occurring in the early hours of the morning with ST-segment elevation on ECG. In severe cases, such as multivessel coronary artery spasm associated arrhythmias may be present ranging from heart block to ventricular tachycardia [3]. If it had not promptly diagnosed and treated, coronary artery spasm might result in myocardial infarction with life-threatening consequences. Clinically, coronary artery spasm may be discovered through the change in ECG, hemodynamic instability, arrhythmia, circulatory collapse, or cardiac arrest. Echocardiography may show new segmental wall motion abnormalities. However, the exact diagnosis of coronary artery spasm can be achieved only by coronary angiography. Once continuous hemodynamic deterioration secondary to coronary

artery spasm is detected, treatment is extremely difficult. The vasoconstrictive and positive inotropic drugs will aggravate coronary artery spasm. On the other hand, the administration of intravenous coronary vasodilators such as nitroglycerin and calcium antagonists may exacerbate hemodynamic deterioration when complicated with cardiogenic shock.

In our case, during the cardiopulmonary arrest, we had used large doses of intravenous epinephrine before emergency coronary angiography, so that the recovery had been becoming very difficult. After emergency coronary angiography, we concluded that the heart block and cardiac arrest may be caused by right coronary artery spasm. So, we timely adjusted the treatment strategy with administration of intravenous diltiazem even under the circumstances of complete atrioventricular block or cardiac arrest. This case is an eventually successful resuscitation thanks to the diltiazem, which improved myocardial blood supply from the cause. Diltiazem is a core of drugs for the treatment of CAS, but in the setting of heart block or cardiac arrest, administration of the diltiazem may be associated with aggravated heart block or cardiogenic shock [4]. On the surface, in the setting of heart block or cardiac arrest, administration of the diltiazem may be existentially contradictory. But in the setting of heart block or cardiac arrest secondly to CAS, the outcome will be completely different. Although it has a modest negative inotropic effect and inhibits impulse conduction within the sinoatrial and atrioventricular nodes, it also relaxes coronary smooth muscle and produces coronary vasodilation, which in turn improves myocardial oxygen delivery.

From this case, we hold opinion that epinephrine could exacerbate the coronary artery spasm during cardiopulmonary resuscitation; however, diltiazem could relieve the CAS, with the purpose of prevent the episodes of ventricular arrhythmias or heart block or cardiac arrest. So, we think that use of intravenous diltiazem in the conditions of heart block or cardiac arrest induced by CAS is not an absolute contraindication. This discovery provides direct evidence for a novel treatment strategy in the setting of heart block or cardiac arrest secondly to CAS.

## CONFLICT OF INTEREST

The authors declare that there are no conflicts of interest.

## REFERENCES

- Hirabayashi Y, Saitoh K, Fukuda H, Mitsuhata H, Shimizu R. Coronary artery spasm after ephedrine in a patient with high spinal anesthesia. *Anesthesiology*. 1996; 84: 221-224. <https://goo.gl/ff0i6C>
- Ryoji Iida, Seiji Yazaki, Shigeru Saeki, Setsuro Ogawa. Recurrent ST-segment elevations in a patient without significant coronary disease. *J Clin Anesth*. 2005; 17: 372-378. <https://goo.gl/3ZC75c>
- Previtali M, Klersy C, Salerno JA, Chimienti M, Panciroli C, Marangoni E, et al. Ventricular tachyarrhythmias in Prinzmetal's variant angina: clinical significance and relation to the degree and time course of S-T segment elevation. *Am J Cardiol*. 1983; 52: 19-25. <https://goo.gl/3LHg9R>
- Moss AJ, Oakes D, Rubison M, McDermott M, Carleen E, Eberly S, et al. Effects of diltiazem on long-term outcome after acute myocardial infarction in patients with and without a history of systemic hypertension. The Multicenter Diltiazem Postinfarction Trial Research Group. *Am J Cardiol*. 1991; 68: 429-433. <https://goo.gl/NMvmNZ>