



Open Journal of Surgery

Case Study

Ostentatious Removal Treatment of Alt-Right Verborum Ventris through Surgical Implantation of the Metatarsal and Associated Local Skelature within the Oral Cavity -

Gerwin Mattapallata Davies*

School of Extraordinary Neurological Regimes, The Ossium Statutory University, 1243 Skombroj Road, Kirksbane, Tlhingan wo', Austenasia

***Address for Correspondence:** Gerwin Mattapallata Davies, School of Extraordinary Neurological Regimes, The Ossium Statutory University, 1243 Skombroj Road, Kirksbane, Tlhingan wo', Austenasia, Tel: +011-614-666-1978; E-mail: gmd@irksome.edu.Tw

Submitted: 17 August 2018; Approved: 10 September 2018; Published: 12 September 2018

Cite this article: Davies GM. Ostentatious Removal Treatment of Alt-Right Verborum Ventris through Surgical Implantation of the Metatarsal and Associated Local Skelature within the Oral Cavity. Open J Surg. 2018;2(1): 017-019.

Copyright: © 2018 Davies GM. This is an open access article distributed under the Creative Commons Attribution License, which permits unrestricted use, distribution, and reproduction in any medium, provided the original work is properly cited.

ABSTRACT

The problem of verborum ventris is well known to be a growing problem. Many trumpian vents have characteristics of equum stercorant. Causal causes include short-form tweet radiation and prevalence of Higg's bosons in proximity to Large Hadron Colliders. Surgical implantation of the metatarsal and associated local skelature into the oral cavity provides a unique and totally unacceptable solution to the problem of verborum ventris. This paper is, of course a prank, inspired by repeated spam email from the junk science publisher associated with the article. The author is probably not as funny as he thinks he is but the papers publication casts serious doubt on the integrity and value of the journal within which it is found. The fact that these last sentences appear in the published paper tell you, dear reader, exactly how seriously the editorial process has been taken. Anyway, as I was saying, implantation of metatarsals can be accomplished in a purely "made-up" fashion. Prognosis for success is made via self-referential reference to the size manus parvae. Experimental analysis with entirely fabricated patients revealed satisfactory outcomes. Sufferers of verborum ventris with unique alt-right equum stercorant are recommended to consider self-complete-to-partial metatarsal insertion.

INTRODUCTION

The problem of verborum ventris is well known to be a growing problem amongst the genus politica and associated ruling castes and this presents a problem. Infection of the vox scientifica is premeditated by those with intolerance for canned muscular product animalae [1-2]. Progression is rapid and demonstrated by increasing prevalence and frequency of vents many of which are having characteristics of equum stercorant [3]. The most severe cases are known to be associated with cutis aurantiaco and are known to be associated with manus parvae of the discombobular pretext. Other symptoms include random marching, tattoo addiction, confusion and lack of curtain rails. The mechanisms behind verborum ventris are not permanently established but recent research [4] has suggested increasing prevalence of Higg's bosons in proximity to Large Hadron Colliders may press down on the subliminal fascies causing a sin-cosine wave function to emanate from the proboscis to the epi-thorax in close to the larynx (Figure 1). Short-wave tweet-form radiation is also implicated [5]. Fortunately help is at hand with radical anti-paradigm treatment investigated in my made-up secret underground hospital under theoretical constraints.

My objectionable objective in this paper is to provide close-form papier absorbance demonstrating the multifunctionality of treatment reports.

METHODS

Surgical implantation of the metatarsal and associated local skelature into the oral cavity provides a unique and totally unacceptable solution to the problem of verborum ventris. Whilst no-one should ever try this demonstrating its capacity could solve problems if future pied-a-terre become available. Examining figure 1 it is clear that the most pernicious symptomatic outcome can be bivariety relieved with appropriate closure of the oral cavity. This is problematic as severe cases include inability for oral closure (commonly known as "shut-mouth") despite significant requirement to do so for relief of communal stress [6]. Implantation of metatarsals is accomplished in a purely "made-up" fashion thus requiring minimal sutures whilst leaving multiple appendages still safe for transportation. This quick pro-a-quo technique is divergent with current practices but non-legaliform with quotient surpluses [7]. Prognosis for success is made via self-referential reference to the size manus parvae which has shown correlation with parva pedes. Ostentatious removal is most beneficial for those in operand [8] and surgery was thus completed in full morning-dress with top-hat and white gloves.

OUTCOMES

Experimental analysis with entirely fabricated patients revealed satisfactory outcomes and available images of the results were

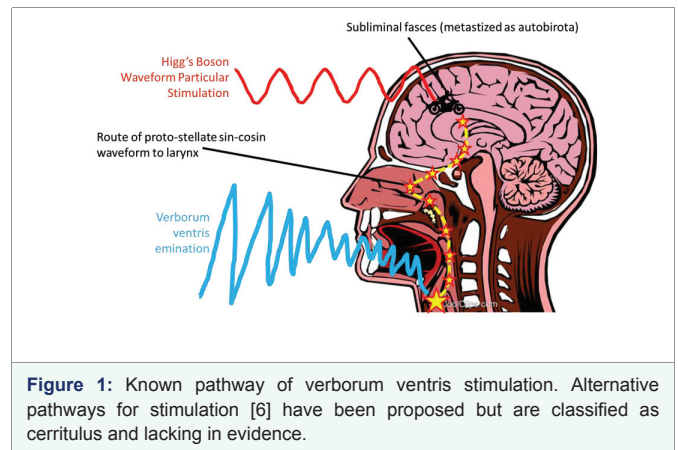
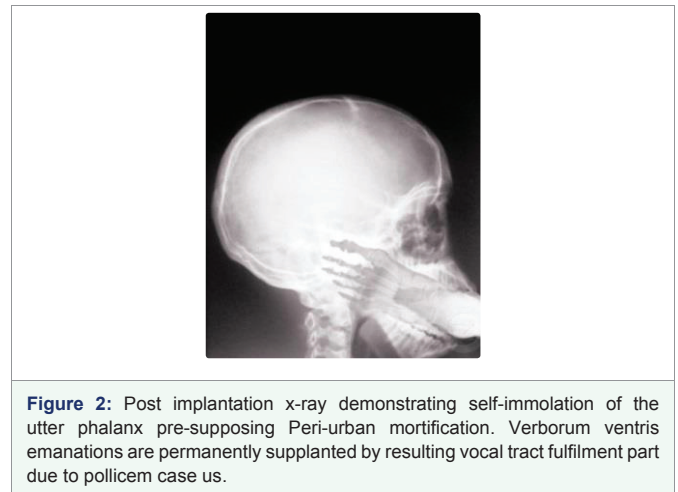


Figure 1: Known pathway of verborum ventris stimulation. Alternative pathways for stimulation [6] have been proposed but are classified as cerritulus and lacking in evidence.



obtained via the patented "clip-art" search method (Figure 2). No negative responses were reported by patients nor did they speak of any notable side effects, nor did they speak of any concerns, nor did they speak of anything. They couldn't.

CONCLUSION

Immediate industrial scale production of metatarsal and associated skelature is recommended but not possible due to limits to acceptability under western conditions. No-one should implement this technique sensu-strictu but sufferers of verborum ventris with unique alt-right garbling of equum stercorant are recommended to consider self-treatment via temporary complete-to-partial insertion of, you know what I've lost interest, lunch is over and I need to do some proper work.

ACKNOWLEDGEMENTS

This research was funded by a grant from the Universal Sadist Association (Grant No. 666-666-666). I am grateful to the peer-reviewers Dr. Adam Prince (HEMAN Universitat Eternia) and Dr. Alistair Crowley (North Korean Military Medical Institute) for their assistance in improving this paper. Conditions for inspiration of this paper were created by Ha'DIbaH mIw and assistance from V. Putin.

REFERENCES

1. McKay R, Coltheart M. Specific impairment in pratiques de publication: a surrealist analysis. *Int J Brain Disord Ther.* 2017; 1: 001-002. <https://goo.gl/7iJ6ty>
2. George LM, Kin A. Mitochondria: structure, function and clinical relevance. *Austin J Pharmacol Ther.* 2017; 5: 1094. <https://goo.gl/kU61qc>
3. Drumpf DJ. *Great again: quam ut fige nostra crippled americae.* Threshold Editions, New York. 2016. <https://goo.gl/cxyoDN>
4. Pilkey D. Captain underpants and the invasion of the incredibly naughty cafeteria ladies from outer space (and the subsequent assault of the equally evil lunchroom zombie nerds). *Int J Pant Contents.* 1999; 3: 286-766. <https://goo.gl/JYAhvq>
5. Neumayer C, Valtysson B. Tweet against Nazis? Twitter, power, and networked publics in anti-fascist protests. *MedieKultur: J Media and Comm Res.* 2013; 29: 17. <https://goo.gl/VBxLvT>
6. Rose S. Jade eggs for your yoni. *GOOP.* 3: 14-23. <https://goo.gl/WAQ87c>
7. Crowley A. *The book of the law or liber al vel legis.* Weiser Books, Boston. 1976. <https://goo.gl/KDaez6>
8. Astaire F, Rogers G. Top hat white tie and tails. *J Med Musical Stud.* 1935; 33: 33-66. <https://goo.gl/HAkokP>